

Manual Therapy and Cervical Arterial Dysfunction, Directions for the Future: A Clinical Perspective

Roger Kerry, MSc (Manipulative Therapy), PGCHE, MMACP, MCSP
Alan J Taylor, MSc (Sports Medicine), MCSP
Jeanette Mitchell, BSc (Physiotherapy), PhD, PGCert(HE), MCSP
Chris McCarthy, PhD, MMACP, MCSP
John Brew, MMACP, MCSP

Abstract: This paper offers a contemporary, evidence-based perspective on the issue of adverse neurovascular events related to cervical spine manual therapy. The purpose of this perspective is to challenge traditional thought and practice and to recognize areas where practice and research should develop. By considering the themes presented in this paper, the clinician can broaden his or her approach to neurovascular assessment in line with contemporary evidence and thought. We present information based on clinically relevant questions. The nature of vertebrobasilar insufficiency and the utility of pre-treatment testing are examined in light of contemporary evidence. In addition, we report on internal carotid artery pathology, and the significance of appreciating atherosclerosis in clinical decision-making. These later two areas are not commonly recognized within manual therapy literature, and we suggest that their importance to differential diagnosis of head and neck pain, as well as estimating treatment related risk, is paramount. We propose that the term cervical arterial dysfunction is more appropriate than classically used nomenclature. This term refers more accurately and completely to the range of pathologies at different anatomical sites that manual therapists treating patients with head and neck pain are likely to encounter. Finally, we present a brief review of the medico-legal status pertaining to this area. Although this is English law-related, the themes derived from this section are of interest to all manual therapists.

Keywords (MeSH): Manual Therapy, Manipulations, Physical Therapy, Atherosclerosis, Vertebrobasilar Insufficiency, Carotid Arteries, Carotid Artery Injury, Risk.

Manual therapy (MT) is a commonly used intervention for the management of cervico-cranial pain¹. Despite evidence demonstrating potential efficacy of this intervention^{2,3}, there are known risks that have been

associated with some aspects of cervical MT⁴. Although numerous types of adverse events have been documented, e.g., injury to the intervertebral disc, ligaments, nerves etc., the cause for most concern is arguably cerebro-vascular events related to stresses on the arterial vessels around the neck; the most common of such events is arguably vertebrobasilar insufficiency (VBI). There is a lack of consensus on the best way to assess for the possibility of adverse events occurring as a result of treatment. Although a number of countries have produced guidelines to assist the clinician in their assessment process⁵, there is still debate on the utility of such protocols^{6,7}. This paper provides a contemporary, evidence-based overview of relevant information to facilitate clinicians understanding of the effect of cervical MT on blood flow. It is hoped that this information will be used in conjunction with

Address all correspondence and requests for reprints to:

Roger Kerry
Division of Physiotherapy Education,
University of Nottingham
Hucknall Road, Nottingham, NG5 1PB, UK
Tel: +44 (0)115 8231790
Fax: +44 (0)115 8231791
E-mail: roger.kerry@nottingham.ac.uk

existing guidelines and knowledge in developing as complete a clinical assessment as possible.

Based on the concepts presented here, we propose a revision of the nomenclature by which we refer to arterial problems of the cervical spine. We suggest the term *cervical arterial dysfunction* (CAD). We believe that this term embraces both the completeness of the arterial anatomy (i.e., the vertebrobasilar system, the internal carotid arteries, and the circle of Willis), and the range of pathologies that the manual therapist may encounter (e.g., local dissection, atherosclerotic events, vessel injury, non-ischemic events, ischemic events). The paper is presented in sections meaningful to clinical practice, and each sub-heading relates to questions typically posed by MT clinicians.

What is the Risk of Arterial Complications Following Manual Therapy?

The actual number of reported cases of arterial complications related to manual treatment of the cervical spine is relatively low. Many authors use the number of published case reports to calculate the ratio of incidents per estimated number of treatments, so they can pass judgment on the *size of the risk*. These calculations range from 1:9122 to 1:5 million (incidents: number of treatments)^{8,9}. The process is, however, an inaccurate and misleading judgment on the size of the risk. Primarily, there is the argument of under-reporting (i.e., not all cases are reported or published). A recent review suggested a 100% under-reporting rate, based on findings of 32 cases within the UK in one year, none of which had been previously reported¹⁰.

Most structured attempts to calculate risk have been made using questionnaire surveys of clinicians. These have either tried to get the clinician to recall past experiences (retrospective surveys^{8,9,11}) or record future experiences over a set period of time (prospective surveys¹²⁻¹⁶). These methodologies are susceptible to a number of flaws, e.g., recall bias, an unwillingness by the clinician to report catastrophic events, an inability (legal or practical) to record such events, data-capture periods that are too short, and a lack of appreciation or clarity as to what counts as an adverse event. These studies are, again, an inaccurate way to establish prevalence.

The paucity of methodologically appropriate studies makes the actual size of the risk impossible to calculate. Figures for prevalence (number of cases in existence) or incidence rate (number of new cases occurring in a year) cannot therefore be stated. All that can be stated is that there is a risk of arterial complications with cervical spine treatment. Large-scale, high-quality, prospective trials are needed to develop understanding of the size of the risk associated with MT treatment. At present, no such studies have been reported. With this in mind, it is necessary for clinical decisions to be made with the information that is

available, and to embrace the uncertainty in which this area of practice is held¹⁷.

What is Vertebrobasilar Insufficiency?

Vertebrobasilar insufficiency (VBI) relates to the transient or permanent reduction or cessation of blood supply to the hindbrain through the left and right vertebral arteries (VA) and the basilar artery¹⁸. Manual therapists have been concerned about this concept for many decades because of the intimate relationship between the course of the VAs and the cervical vertebral column. Particular concern has been given to the effect that upper cervical spine rotation has on blood flow in the VAs. Figure 1 demonstrates the distortion that right upper cervical rotation can produce on the left VA. It is this transient stress during movement that is thought to be the mechanism by which VBI is caused—either through a single trauma event or through repeated movements. Further details of the effect of movement on blood flow are given below.

Traditionally, VBI was said to result in transient episodes of hindbrain ischemia manifesting in a number of cardinal signs conventionally referred to as Coman's 5 Ds¹⁹. However, clinical presentations of transient hindbrain ischemia are more diverse than these classically quoted cardinal signs. Table 1 provides a more complete review of signs and symptoms known to be associated with both local vertebrobasilar vessel damage and hindbrain ischemia. Of great importance for the manual therapist is the fact that neck and head pain is a commonly reported symptom related to arterial dissection. It is with this in mind that the clinician must be vigilant to the fact that patients with an existing arterial dissection may seek care from a manual therapist.

Is Functional Pre-Treatment Screening Useful?

Functional positional tests are often used to screen for the presence of VBI. Recent Australian Physiotherapy Association guidelines^{5,14} reviewed existing guidance of the screening test and suggested that functional testing should consist of sustained cervical rotation, as a minimum requirement. The idea of this, and variations on this theme, is that if blood flow can be altered in a controlled way (by carefully and vigilantly rotating the neck), cardinal signs of insufficiency can be observed. If such signs manifest, then certain treatments are contra-indicated. Current literature provides little support for the validity or reliability of these tests.

Many blood flow studies have demonstrated a change (reduction) in blood flow in the contralateral VA during rotation²⁰⁻²⁸. Other studies, however, have found no change in blood flow²⁹⁻³². Some authors have used the results of studies demonstrating a reduction in blood flow to support the validity of screening tests; i.e., one tests to assess blood flow

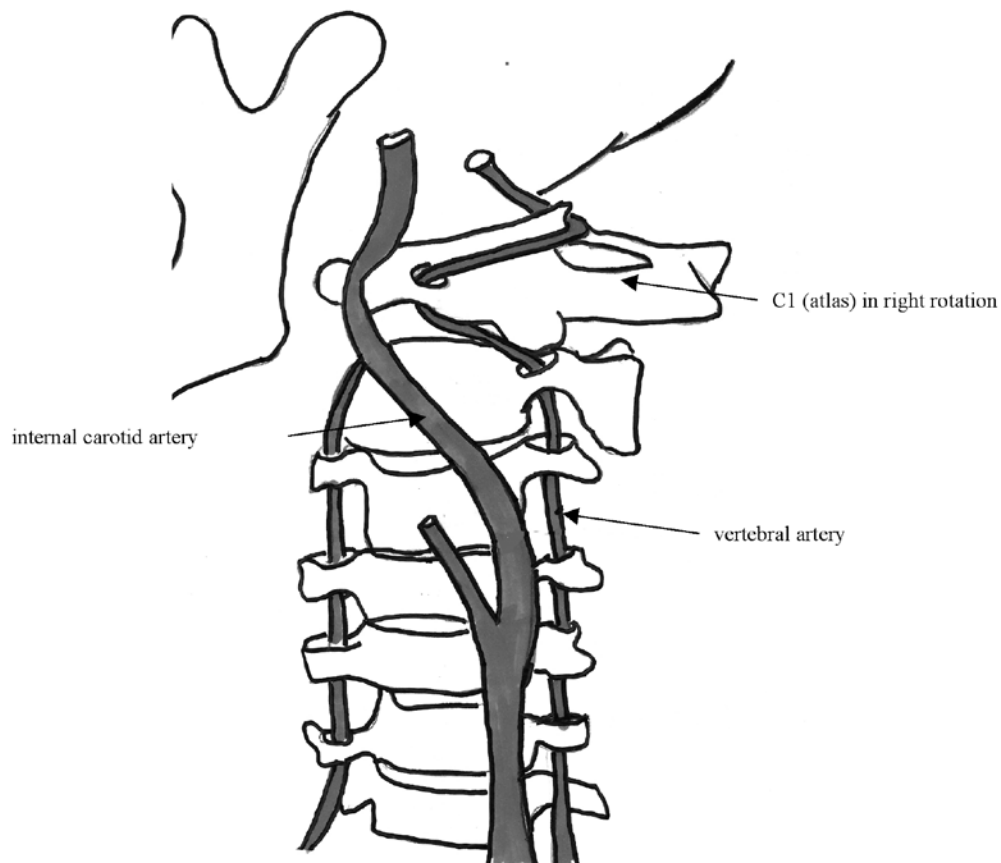


Fig. 1: Vertebral (and internal carotid) arteries during upper cervical rotation (Reprinted with the permission of NCMIC Group, Inc. No further reproduction is allowed without the express permission of NCMIC.)

TABLE 1. Reported signs and symptoms of vertebrobasilar insufficiency (hindbrain ischemia)

Condition	Symptoms
Local vertebrobasilar vessel damage and hindbrain ischemia	Anhidrosis (lack of facial sweating) Ataxia Clumsiness and agitation Diplopia Dizziness Drop attacks Dysarthria Dysphagia Facial numbness Hearing disturbances Hoarseness Hypotonia/limb weakness (arm or leg) Loss of short-term memory Malaise Nausea Nystagmus Pallor/tremor Papillary changes Perioral dyesthesia Photophobia Vagueness Vomiting

changes, these studies demonstrate that rotation changes blood flow; therefore, the test is valid. The tests may be valid in that they may alter blood flow, but there is little consistent evidence relating these changes to changes in symptoms; e.g., a patient could have significant reduction in blood flow but no symptoms and vice versa. This makes the specificity and sensitivity of these tests poor and variable, and this has been mathematically demonstrated in probability calculations³³⁻³⁵. On the basis of the inconsistency of the evidence, a recent paper has raised the issue of whether manual therapists should stop using functional pre-screening tests³⁶. The opinion that the use of functional pre-screening testing cannot be supported has been highlighted again in the evidence reviewed for this present project.

There is no evidence to support the construct validity of functional pre-screening testing in terms of its ability to identify patients who are more likely to have spontaneous dissection events. This test is, of course, specific to the vertebrobasilar system and unlikely to be sensitive to ICA blood flow changes.

Internal Carotid Artery (ICA) Dysfunction

Complications of MT treatment related to the ICAs have been reported^{10,37}. Consideration of the reported cases alone will not lead to a full understanding of the complete nature and details of ICA pathologies. However, there is a significant amount of information available that manual therapists can exploit to understand problems associated with the ICA. This is summarized below so that the clinician is able to make informed judgments on the differential diagnosis of presentations that may be associated with ICA dysfunction. Figure 2 shows the anatomical course of the ICA.

The ICA supplies the brain and the retina. The natural onset and progress of ICA dissection begins with local arterial trauma (the dissection event itself). This dissection event can manifest in a number of signs and symptoms that are non-ischemic (i.e., somatic pain related to local injury). These local signs and symptoms can precede cerebral ischemia (TIA or stroke) or retinal ischemia by anything from less than a week to beyond 30 days^{38,39}. There is, therefore, a

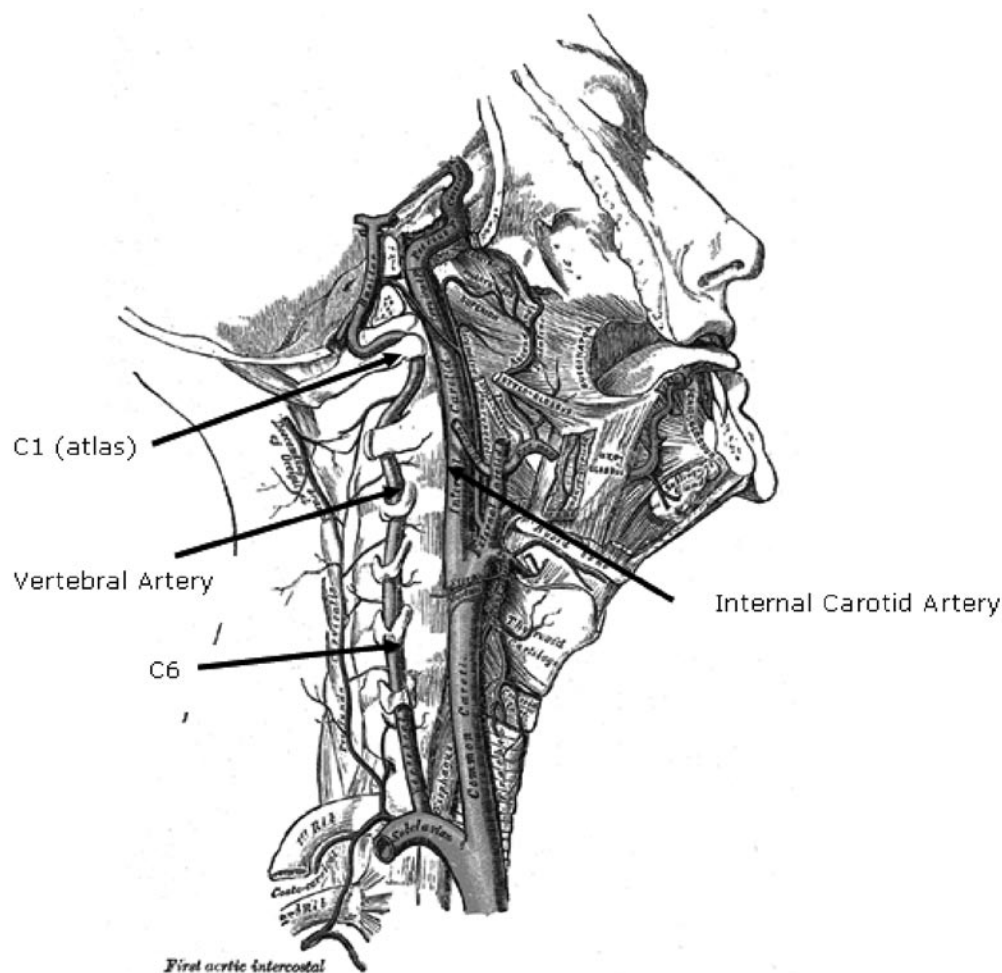


Fig. 2: Course of the vertebral and internal carotid arteries through the cervical spine. (Adapted with permission from, Drake et al, Gray's Anatomy for Students, www.studentconsult.com, Elsevier Ltd.)

TABLE 2. Clinical features of ICA dissection. Non-ischemic signs and symptoms may precede cerebral/retinal ischemia by anything from a few days to over a month⁷¹

Non-ischemic (local) signs/symptoms	Ischemic (cerebral or retinal) signs/symptoms
<ul style="list-style-type: none"> • Horner's syndrome • Pulsatile tinnitus • Cranial nerve palsies (most commonly CN IX to XII) <p>Less common local signs and symptoms include:</p> <ul style="list-style-type: none"> • Ipsilateral carotid bruit • Scalp tenderness • Neck swelling • CN VI palsy • Orbital pain • Anhidrosis (facial dryness) 	<ul style="list-style-type: none"> • Transient ischemic attack (TIA) • Ischemic stroke (usually middle cerebral artery territory) • Retinal infarction • Amaurosis fugax

Copyright (2006), reprinted with permission from Elsevier

period of time when a patient with ICA dissection may present to the manual therapist with signs and symptoms that may mimic a neuromusculoskeletal presentation³⁷. Table 2 details classic ICA non-ischemic and ischemic manifestations of ICA dissection.

It is important to appreciate that similar to a VA dysfunction, headache and/or cervical pain can be the sole presentation of ICA dysfunction—particularly in the early stages of the pathology^{37,40,41}.

Cranial nerve palsies and Horner's syndrome are often pathognomonic of ICA pathology, especially if the onset is acute. The hypoglossal nerve (CN XII) is the most commonly affected followed by the glossopharyngeal (CN IX), vagus (CN X), or accessory (CN XI)^{39,42}. However, all cranial nerves (except the olfactory nerve) can be affected³⁹. Horner's syndrome—characterized by drooping eyelid (ptosis), sunken eye (enophthalmia), a small, constricted pupil (miosis), and facial dryness (anhidrosis)—has been found to be present in up to 82% of patients with known ICA dissection⁴³. Most commonly, this syndrome occurs with head, neck, or facial pain.

Can We Identify “At-Risk” Patients?

Cervical arterial dysfunction (CAD) refers to a wide variety of pathophysiological events affecting both the vertebrobasilar and the carotid vessels. At one extreme are actual cerebrovascular accidents (CVA) (strokes). In the middle of the continuum are the much more subtle dysfunctions relating to transient interruption of perfusion to particular sites in the head, while at the other end of the continuum is the consideration of the patient's likelihood to be at risk from a future cervico-cranial ischemic event and the need to calculate the

chances of physiotherapy intervention contributing to such an event. It is essential that clinicians consider the full scope of this continuum. At-risk patients may, therefore, be either those presenting with frank arterial pathology or those with no clinical pathology but with a high number of *vascular* risk factors. A multi-factorial approach must therefore be taken in the assessment of these patients, and reliance on single, physical tests with known poor utility represents an incomplete and misleading examination.

History-taking may assist in establishing which patients are at risk of CAD and, therefore, at an increased risk from cervical MT. The latest Australian Physiotherapy Association guidelines emphasize this point⁵. It has been suggested that, for VBI at least, there are no identifiable predictors of adverse outcome and the phenomenon is an unpredictable, idiosyncratic event whose pathology is possibly inherent⁴⁴. Despite this single study, there is a wealth of information outside the MT literature that may help us to begin to identify patients who are more at risk of CAD than others, e.g., those with the symptomology of pathologies as detailed above. More specifically, this information can help us differentiate those people presenting with pain (with or without other signs and symptoms) of a vascular origin.

With the exception of truly unidentifiable genetic vascular dysfunction (e.g. hypoplasia, fibrodysplasia⁴⁵), which may account for rare random spontaneous dissection events, the basis for almost all other cervical vascular conditions is pathology of the endothelium, specifically atherosclerosis.

Atherosclerosis is intrinsically related to endothelial dysfunction. It is a cascade of inflammatory events influenced by conventional inflammatory mediators and infectious micro-organisms. These events are triggered by endothelial changes induced by chemical, mechanical, or immunological insult⁴⁶⁻⁴⁸. Evidence-based clinical athero-

sclerotic risk factors include hypertension; diabetes; family history of atherosclerotic-related pathologies (e.g. heart disease, stroke, transient ischemic attack, peripheral vascular disease); smoking, high serum low density lipoprotein (hypercholesterolemia/hyperlipidemia/high cholesterol-high fat diet); hyperhomocysteinemia; infection by escherichia coli, helicobacter pylori, chlamydia pneumoniae, streptococcus, staphylococcus, salmonella, clostridium, mycobacterium, fungi, yersenia, treponema; and mechanical trauma to vessel⁴⁶⁻⁵⁵.

The logic for considering this in cervical MT is simple and is based on the following premises:

- 1) Atherosclerosis is strongly linked with localized ICA⁵⁶⁻⁵⁹ and VA⁶⁰⁻⁶⁴ dysfunction, and ultimately stroke as a result of this localized dysfunction.
- 2) Cervical movement affects blood flow in these vessels (see above).
- 3) Cervical trauma is associated with the aetiology and progression of CAD⁶⁵⁻⁶⁹.
- 4) Neck and head pain is a common early manifestation of dysfunctional cervical arteries (see above).
- 5) Manual therapists see patients with neck and head pain and histories of cervical trauma.
- 6) Manual therapists have the ability to produce further cervical trauma through various treatment interventions.

This logic provides the basis for our suggestion that, despite comments to the contrary^{44,70}, consideration of atherosclerotic risk factors when profiling for high-risk patients, or when differentially diagnosing pain syndromes, should remain a concern of the manual therapist. We propose that until there is substantial evidence to refute this suggestion, the overwhelming extent of pathophysiological and epidemiological knowledge regarding cervical arterial atherosclerosis would make it professionally irresponsible for clinicians to ignore this dimension of CAD.

It is beyond the scope of this paper to detail the technicalities of assessment for atherosclerotic profiling. However, consideration of the above risk factors in the history taking, and the use of blood pressure testing, for example, are important components to be integrated into MT practice^{71,72}.

What is the Relative Risk of Manipulating the Upper Cervical Spine Versus the Lower Cervical Spine?

There are no studies in the current literature that focus directly on this question. Traditionally, the upper cervical spine is believed to carry a greater risk because of the tortuous course of the VA between C2 and the occiput. Most blood

flow studies have concentrated on the C1/C2 and cervical anatomical area^{25,29,30,32,73-75}. Some flow studies have insonated the vessel as it enters the lower part of the vertebral column (the pre-transverse level)^{22,76-80}. Few studies have measured blood flow in the intracranial VA^{21,23,24,28} where it may be argued that VA blood flow related to the upper cervical spine would be a more accurate measure of flow change^{24,32,73,74}.

It has also been shown that VA atherosclerotic plaques do exist throughout the course of the VA⁶⁴. On the other hand, ICA plaques are most prevalent around the bifurcation of the internal/external vessels, this is usually around the mid/low cervical spine, around the bifurcation of the common carotid artery⁸¹. Atherosclerotic lesions are thought to be, overall, more common in the anterior (carotid) system than the posterior (vertebral) system. Therefore, it is not possible to provide a definitive answer to the above question based on the literature. Theoretically, although it is likely that upper cervical MT carries the greater risk, the low/mid cervical spine cannot be considered as being completely safe.

Is Physiotherapy Manual Therapy as Risky as Manipulative Treatment used by other Groups (e.g., Chiropractic)?

Most MT case reports and surveys involve chiropractic care and refer to manipulative thrust techniques of various forms. This, together with the fact that chiropractors arguably carry out a far greater number of manipulations than osteopaths or physiotherapists, leads many authors to conclude that chiropractic treatment carries the greatest risk. Although there is some logic in this conclusion, it does not support the idea that less forceful, or non-chiropractic treatment, is necessarily safer. Blood flow studies have demonstrated significant flow changes during gentle passive positioning and not fast, manipulative procedures of the cervical spine.

One cause of hindbrain ischemic events is believed to be dissection of an atherosclerotic thrombus. Although a quicker movement (manipulative thrust) is more likely to dissect a thrombus, it is also feasible, based on the results of flow studies, that gentler, repeated movements offer a potential dissection-inducing force. Due to the progressive nature of atherosclerotic pathology, ischemic events (e.g., embolization following thrombus formation and thrombus dissection) may occur some time after treatment^{38,39,42}. This latency concept will affect the true incidence rate in all MT groups.

In summary, although there are more chiropractic-related cases reported, this evidence is arguably disproportionate. Non-manipulative, MT treatment, and other forms of *hands-off* physiotherapy have not been subject to the same degree of study and so no judgment can be made regarding this risk.

What is the Medico-Legal Situation Regarding Treatment and the Role of Guidelines?

In English law, the mere fact that a procedure is unsuccessful or goes wrong does not necessarily mean that the duty of care a health care professional owes to the patient has been breached. The court informs itself regarding whether there has been a failure to provide the required standard of care by hearing expert testimony from the profession concerned. If it can be shown that what the defendant did was in accord with a practice currently accepted as proper within his or her profession at the time of the incident, it is unlikely the professional will be held to have acted negligently even if there is another currently accepted but contrary practice⁸². Expert opinions may, however, be scrutinized under cross-examination and the court may disregard a practice, despite it being currently accepted, if it considers it to be unreasonable, irresponsible, or logically indefensible. In particular it needs to be satisfied that in forming their views, witnesses “have directed their minds to the question of comparative risks and benefits”⁸³. If the defendant cannot show that he or she has followed an accepted practice, it falls to him or her to justify what he or she did. The more serious the harm suffered, the more robust that defense will have to be.

Despite the fact that a primary aim of guidelines is to ensure that all the right things and none of the wrong things are done when a patient presents with a particular clinical problem⁸⁴, a guideline has no particular status or automatic effect in English law, and if reliance is to be placed on it, its existence and content must be brought to the court’s notice as part of the expert testimony mentioned above⁸⁵. Nor does the mere existence of a guideline guarantee that the quoted aim has been met since a lack of consistency in the quality of evidential bases and methodology can render its authority and clinical trustworthiness suspect⁸⁶. The worth of a particular guideline remains a matter for individual clinical judgment as does the decision to follow or depart from it in practice.

Summary

Serious adverse neurovascular responses are a rare but as yet unquantified consequence of cervical MT. Although this number of reported cases of serious adverse effects is low, a number of factors prevent using these cases to estimate the prevalence or incidence of this phenomenon, e.g., latency of pathology, lack of clarity regarding presentations, ambiguity regarding what is an adverse neurovascular event, etc. Surveys of MT practitioners are an inaccurate method of attempting to establish size of risk. The true size of these adverse events cannot be estimated at this time.

Traditional clinical practice has focused on pre-manipulative screening for the presence or absence of vertebral insufficiency. Despite concerns about the utility of VBI screening tests, they are still relied upon in clinical decision-making. We have proposed that the clinical approach should be broadened to incorporate not only VBI but also pathologies affecting the ICAs. Furthermore, we suggest that this clinical approach embraces differential diagnosis of known arterial pathologies that commonly present with neck and/or head pain. The underlying pathologies affecting all parts of the cervical arterial system are varied, but most known cervical arterial complications are atherosclerotic in nature. The exception to this is rare spontaneous dissection. With this in mind, we suggest that consideration of atherosclerotic risk factors may enhance decision-making with regards to both pre-treatment screening and differential diagnosis of frank arterial pathology.

The evidence surrounding cervical arterial dysfunction and MT is varied and inconclusive. As clinicians responsible for the health of our patients, we must strive to use the best information available. This information must be incorporated into our own clinical reasoning processes. In the absence of strong evidence-based guidelines, we must embrace the uncertainty of this clinical area and use our reasoning to do the best for our patients. First, we must do no harm.

Key Messages

- Traditional cardinal signs and symptoms of VBI following MT are not supported by the literature.
- The real risk of arterial complications following MT is unknown and impossible to estimate, based on existing data.
- The results of blood flow studies are contradictory and inconclusive. Commonly used functional screening tests are not supported by the data available from these studies, nor from case reports.
- Consideration of haemodynamics related to the cervical region may enhance clinicians’ understanding of risks and mechanisms of vascular events.
- Adherence to guidelines might not necessarily be a defense, and expert opinion can be over-ruled in law.

Recommendations

- We propose the term *cervical arterial dysfunction* (CAD) to embrace the whole cervical arterial system and the range of pathologies that affect this system.
- Consideration of atherosclerotic risk factors may assist in identifying at-risk patients and patients presenting with

frank arterial pathology. We recommend the use of specific questioning and testing—specifically blood pressure measurement—to facilitate risk-factor profiling.

- Knowledge of known arterial presentations will strengthen

the clinician's differential diagnosis skills. We recommend the incorporation of this knowledge, and testing procedures such as cranial nerve examination, to facilitate differential diagnosis. ■

REFERENCES

1. Gross AR, Kay T, Hondras M. Manual therapy for mechanical neck disorders: A systematic review. *Man Ther* 2002;7:131–149.
2. Brontfort G, Assesdelft WJ, Evans R, Haas M, Bouter L. Efficacy of spinal manipulation for chronic headache: A systematic review. *J Manip Physiol Ther* 2001;24:457–466.
3. Gross AR, Hoving JL, Haines JL. A Cochrane review of manipulation and mobilization for mechanical neck disorders. *Spine* 2004;29:1541–1548.
4. Ernst E. Adverse effects of spinal manipulation: A systematic review. *J R Soc Med* 2007;100:330–338.
5. Australian Physiotherapy Association. Clinical guidelines for assessing vertebrobasilar insufficiency in the management of cervical spine disorders. APA 2006; <http://apa.advsol.com.au/members/documents/download/AssessingVertebrobasilarInsuffic.pdf>.
6. (AJP) AJoP. Pre-manipulative testing of the cervical spine; Forum. *Aust J Physiother* 2001;47:163–168.
7. Kerry R. Pre-manipulative procedures for the cervical spine: New guidelines and a time for dialectics: knowledge, risks, evidence and consent. *Physiother* 2002;88:417–420.
8. Haynes MJ. Stroke following cervical manipulation in Perth. *Chiro J of Aust* 1994;24:42–46.
9. Michaeli A. Reported occurrence and nature of complications following manipulative physiotherapy in South Africa. *Aust J Physiother* 1993;39:309–315.
10. Ernst E. Cerebrovascular complications associated with spinal manipulation. *Phys Ther Rev* 2004;9:5–15.
11. Rivett DA, Milburn P. A prospective study of complications of cervical spine manipulation. *J Manip Physiol Ther* 1996;4:166–170.
12. Dupeyron A, Vautravers JL, Isner-Horobeti ME. Complications following vertebral manipulation: A survey of a French region physicians. *Ann de Readaptation et de Medicine Physique* 2003;46:33–40.
13. Leboeuf-Yde C, Hennius B, Rudberg E, Leufvenmark P, Thunmann M. Side effects of chiropractic treatment: A prospective study. *J Manip Physiol Ther* 1997;20:511–515.
14. Magarey ME, Rebbeck T, Coughlan B, Grimmer K, Rivett DA, Refshauge K. Pre-manipulative testing of the cervical spine: Review, revision and new clinical guidelines. *Man Ther* 2004;9:95–108.
15. Nadareishvili Z, Norris JW. Stroke from traumatic arterial dissection. *The Lancet* 1999;354:159–160.
16. Stevinson C, Honan W, Cooke B, Ernst E. Neurological complications of cervical spine manipulation. *J R Soc Med* 2001;94:107–110.
17. Childs JD, Flynn TW, Fritz JM, et al. Screening for vertebrobasilar insufficiency in patients with neck pain: Manual therapy decision-making in the presence of uncertainty. *J Orthop Sports Phys* 2005;35:300–306.
18. Rivett DA. The vertebral artery and vertebrobasilar insufficiency. In: Boyling J, Jull G, eds. *Grieve's Modern Manual Therapy*. 3rd ed. Edinburgh, UK: Churchill Livingstone, 2005.
19. Coman WB. Dizziness related to ENT conditions. In: Grieve GP, ed. *Modern Manual Therapy of the Vertebral Column*. Edinburgh, UK: Churchill Livingstone, 1986.
20. Arnold C, Bourassa T, Langer T, Stoneham G. Doppler studies evaluating the effect of a physical therapy screening protocol on vertebral artery blood flow. *Man Ther* 2004;9:13–21.
21. Li YK, Zhang YK, Lu CM, Zhong SZ. Changes and implications of the blood flow velocity of the vertebral artery during rotation and extension of the head. *J Manip Physiol Ther* 1999;22:91–95.
22. Licht PB, Christensen HW, Højgaard P, Høilund-Carlsen PF. Triplex ultrasound of vertebral artery flow during cervical rotation. *J Manip Physiol Ther* 1998;21:27–31.
23. Mitchell J. Changes in vertebral artery blood flow following normal rotation of the cervical spine. *J Manip Physiol Ther* 2003;26:347–351.
24. Mitchell J, Keene D, Dyson C, Harvey L, Prueve C, Phillips R. Is cervical spine rotation, as used in the standard vertebrobasilar insufficiency test, associated with a measurable change in intracranial vertebral artery blood flow? *Man Ther* 2004;9:220–227.
25. Refshauge KM. Rotation: A valid pre-manipulative dizziness test? Does it predict safe manipulation? *J Manip Physiol Ther* 1994;17:15–19.
26. Rivett DA, Milburn PD, Chapple C. Negative pre-manipulative vertebral artery testing despite complete occlusion: A case of false negativity? *Man Ther* 1998;3:102–107.
27. Rivett DA, Reid D. Risk of stroke for cervical spine manipulation in New Zealand. *New Zeal J Phys* 1998;26:14–17.
28. Rossitti S, Volkmann R. Changes of blood flow velocity indicating mechanical compression of the vertebral arteries during rotation of the head in the normal human measured with transcranial Doppler sonography. *Arquivos de Neuro-Psiquiatria* 1995;53:26–33.
29. Haynes MJ, Milne N. Color Duplex sonographic findings in human vertebral arteries during cervical rotation. *J Clin Ultrasound* 2001;29:14–24.
30. Thiel H, Wallace K, Donat J, Yong-Hing K. Effect of various head and neck positions on vertebral artery blood flow. *Clin Biomech* 1994;9:105–110.
31. Weingart JR, Bischoff HP. Doppler sonography of the vertebral artery with regard to head positions appropriate to manual medicine. *Manuelle Medizin* 1992;30:62–65.
32. Zaina C, Grant R, Johnson C, Dansie B, Taylor J, Spyropolous P. The effect of cervical rotation on blood flow in the contralateral vertebral artery. *Man Ther* 2003;8:103–109.
33. Gross AR, Chesworth B, Binkley J. *A Case for Evidence-Based Practice in Manual Therapy*. 3rd ed. Edinburgh, UK: Elsevier Churchill Livingstone, 2005.
34. Kerry R, Rushton A. Decision theory in physical therapy. *14th International WCPT Congress*. 2003. Barcelona, Spain.
35. Ritcher RR, Reinking MF. How does evidence on the diagnostic accuracy of the vertebral artery test influence teaching of a test in a professional physical therapist education program? *Phys Ther Rev* 2005;85:588–599.

36. Thiel H, Rix G. Is it time to stop functional pre-manipulative testing of the cervical spine? *Man Ther* 2004;10:154–158.
37. Taylor AJ, Kerry R. Neck pain and headache as a result of internal carotid artery dissection: Implications for clinicians. *Man Ther* 2005;10:73–77.
38. Biousse V, D'Anglejan-Chatillon J, Massiou H. Head pain in non-traumatic artery dissection: A series of 65 patients. *Cephalgia* 1994;14:33–36.
39. Zetterling M, Carlstrom C, Konrad P. Internal carotid artery dissection. *Acta Neurol Scand* 2000;101:1–7.
40. Pezzini A, Granella F, Grassi M, et al. History of migraine and the risk of spontaneous cervical artery dissection. *Cephalgia* 2005;25:575–580.
41. Rogalewski A, Evers S. Symptomatic *hemispheric continua* after internal carotid artery dissection. *Headache* 2005;45:167–169.
42. Arnold M, Bousser MG. Carotid and vertebral dissection. *Pract Neurol* 2005;5:100–109.
43. Chan CK, Paine M, O'Day J. Carotid dissection: A common cause of Horner's syndrome. *Clin Exp Ophthalmol* 2001;29:411–415.
44. Halderman S, Kohlbeck FJ, McGregor M. Unpredictability of cerebrovascular ischemia associated with cervical spine manipulation therapy: A review of 64 cases after cervical spine manipulation. *Spine* 2002;27:49–55.
45. Chuang YM, Huang YC, Hu HH, Yang CY. Toward a further elucidation: Role of vertebral artery hypoplasia in acute ischemic stroke. *Eur Neurol* 2006;55:193–197.
46. Kaperonis EA, Liapis CD, Kakisis JD, Dimitroulis D, Papavassiliou VG. Inflammation and atherosclerosis. *Eur J Endovasc Surgery* 2006;31:386–393.
47. Ross R. Atherosclerosis: An inflammatory disease. *New Engl J Med* 1999;340:115–126.
48. Tahara N, Kai H, Nakaura H, et al. The prevalence of inflammation in carotid atherosclerosis: Analysis with fluorodeoxyglucose-positron emission tomography. *Eur Heart J* 2007; ehm 245 ahead of publication.
49. Cameron JD, Cruickshank JF. Glucose, insulin, diabetes and mechanisms of arterial dysfunction. *Clin Exper Pharm Phys* 2007;34:677–682.
50. Grewal J, Anand S, Islam S, Lonn E. Prevalence and predictors of subclinical atherosclerosis among asymptomatic "low risk" individuals in a multiethnic population. *Atherosclerosis* 2007; ATH-10020 ahead of publication.
51. Hayward CS, Benetos A. Hereditary and environmental influences on arterial function. *Clin Exper Pharm Phys* 2007;37:658–664.
52. Kingwell B, Boutouyrie P. Genetic influences on the arterial wall. *Clin Exper Pharm Phys* 2007;37:652–657.
53. McEniery CM, Wilkinson IB, Avolio AP. Age, hypertension and arterial function. *Clin Exper Pharm Phys* 2007;37:665–671.
54. Stoll G, Bendszus M. Inflammation and atherosclerosis: Novel insights into plaque formation and destabilization. *Stroke* 2006;37:1923–1932.
55. Zoungas S, Asmar RP. Arterial stiffness and cardiovascular outcome. *Clin Exper Pharm Phys* 2007;37:647–651.
56. Jerrard-Dunne P, Markus HS, Steckel DA, Buehler A, von Kegler S, Sitzer M. Early carotid atherosclerosis and family history of vascular disease: Specific effects on arterial sites have implications for genetic studies. *Atheroscler Thromb Vasc Biol* 2003;23:203–306.
57. Kakkos SK, Nicolaidis A, Griffin M, et al. The asymptomatic carotid stenosis and risk of stroke (ACSRS) study group. Factors associated with mortality in patients with asymptomatic carotid stenosis: Results from the ACSRS Study. *Int Angiol* 2005;24:221–230.
58. Lee EJ, Kim HJ, Bae JM. Relevance of common carotid intima-media thickness and carotid plaque as risk factors for ischemic stroke in patients with type 2 diabetes mellitus. *Am J Neuroradiol* 2007;28:916–919.
59. Paraskevas KI, Mikhailidis DP, Liapis CD. Internal carotid artery occlusion: Association with atherosclerotic disease in other arterial beds and vascular risk factors. *Angiology* 2007;58:329–335.
60. Cagnie B, Barbaix E, Vinck E, D'Herde K, Cambier D. Atherosclerosis in the vertebral artery: An intrinsic risk factor in the use of spinal manipulation? *Surg Radiol Anat* 2006;28:129–134.
61. Canyigit M, Arat A, Cil BE, et al. Distal embolization after stenting of the vertebral artery: Diffusion-weighted MRI findings. *Cardiovasc Intervent Radiol* 2007;30:189–195.
62. Dickerman RD, Reynolds A, East JW. The vertebral artery: Know the high risk patients. *Surg Radiol Anat* 2006;28:129–134.
63. Koch S, Amir M, Rabinstein AA, Reyes-Iglesia YR, Romano JG, Forteza A. Diffusion-weighted magnetic resonance imaging in symptomatic vertebrobasilar atherosclerosis and dissection. *Arch Neurol* 2005;62:1228–1231.
64. Mitchell J. Vertebral artery atherosclerosis: A risk factor in the use of manipulative therapy? *Physio Res Int* 2002;7:122–135.
65. Caso V, Paciaroni M, Bogousslavsky J. Environmental factors and cervical artery dissection: Front. *Neurol Neurosci* 2005;20:44–53.
66. Garg A, Gaikwar SB, Kanodia A, Suri A, Gupta V, Mishra NK. Positional occlusion/stasis of vertebral arteries in a case of cervical rheumatoid arthritis presenting with multiple posterior circulation infarcts. *Spine* 2004;29:E321–325.
67. Tominaga T, Takahashi T, Shimizu H, Yoshimoto T. Rotational vertebral artery occlusion from occipital bone anomaly: A rare cause of embolic stroke. *J Neurosurg* 2002;97:1456–1459.
68. Volle E, Montazem A. MRI video diagnosis and surgical therapy of soft tissue trauma to the cervical junction. *Ear Nose Throat J* 2001;80:41–44.
69. Yamazaki M, Okawa A, Aramoni MA, Hasimoto M, Masaki Y, Koda M. Fenestration of vertebral artery at the craniovertebral junction in Down syndrome: A case report. *Spine* 2004;29:E551–554.
70. Bartels E. Dissection of the extracranial vertebral artery: Clinical findings and early non-invasive diagnosis in 24 patients. *J Neuroimaging* 2006;16:24–33.
71. Kerry R, Taylor AJ. Cervical arterial dysfunction assessment and manual therapy. *Man Ther* 2006;11:243–253.
72. Kerry R, Taylor AJ. Headache and neck pain: A sign of underlying vascular pathology? *In Touch* 2006;114:2–8.
73. Mitchell J. Is mechanical deformation of the suboccipital vertebral artery during cervical spine rotation responsible for vertebrobasilar insufficiency? *Physio Res Int* 2007a; <http://www.interscience.wiley.com>, DOI: 10.1002/pri.370 [May 15 2007].
74. Mitchell J. Doppler insonation of vertebral artery blood flow changes associated with cervical spine rotation: Implications for manual therapists. *Physio Theo Prac* 2007b; in press.
75. Rivett DA, Sharples KJ, Milburn PD. Effect of pre-manipulative tests on vertebral artery and internal carotid artery blood flow: A pilot study. *J Manip Physiol Ther* 1999;22:368–375.
76. Licht PB, Christensen HW, Hoilund-Carlsen PF. Vertebral artery volume flow in human beings. *J Manip Physiol Ther* 1999;22:363–367.
77. Licht PB, Christensen HW, Hoilund-Carlsen PF. Is there a role for pre-manipulative testing before cervical manipulation? *J Manip Physiol Ther* 2000;23:175–179.
78. Licht PB, Christensen HW, Hoilund-Carlsen PF. Carotid artery blood flow during pre-manipulative testing. *J Manip Physiol Ther* 2002;25:568–572.

79. Licht PB, Christensen HW, Hojgaard P, Marving J. Vertebral artery flow and spinal manipulation: A randomized, controlled and observer-blinded study. *J Manip Physiol Ther* 1998;21:141–144.
 80. Licht PB, Christensen HW, Svendsen P, Hoilund-Carlsen PF. Vertebral artery flow and cervical manipulation: An experimental study. *J Manip Physiol Ther* 1999;22:431–435.
 81. Lorenz MW. Carotid intima-media thickening indicates a higher vascular risk across a wide age range: Prospective data from the carotid atherosclerosis progression study (CAPS). *Stroke* 2006;37:87–92.
 82. Bolam v Friern Hospital Management Committee. 1 WLR 582. 1957.
 83. Bolitho v City and Hackney HA. All ER 771. 1997.
 84. Tuffnell DJ. *Why Clinical Guidelines? A Medical Perspective*. London, UK: Cavendish, 2002.
 85. Foster C. *Civil Procedure, Trial Issues and Clinical Guidelines*. In: *Clinical Guidelines: Law, Policy and Practice*. London: Cavendish, 2002.
 86. Hurwitz B. How does evidence based guidance influence determinations of medical negligence? *Brit Med J* 2004;329:1024–1028.
-